

■ ASPECTS OF CURRENT MANAGEMENT

Osteotomies around the knee

PATIENT SELECTION, STABILITY OF FIXATION AND BONE HEALING IN HIGH TIBIAL OSTEOTOMIES

J.-M. Brinkman,
P. Lobenhoffer,
J. D. Agneskirchner,
A. E. Staubli,
A. B. Wymenga,
R. J. van
Heerwaarden

*From the Limb
Deformity
Reconstruction Unit,
Nijmegen, The
Netherlands*

New developments in osteotomy techniques and methods of fixation have caused a revival of interest of osteotomies around the knee. The current consensus on the indications, patient selection and the factors influencing the outcome after high tibial osteotomy is presented. This paper highlights recent research aimed at joint pressure redistribution, fixation stability and bone healing that has led to improved surgical techniques and a decrease of post-operative time to full weight-bearing.

Osteotomy around the knee was a well-established technique in the treatment of unicompartamental osteoarthritis of the knee.¹ Later it was almost entirely replaced because of the success of total and unicompartamental knee replacement (TKR and UKR). Compared to replacements, osteotomy was considered a demanding procedure with an unpredictable outcome and associated with significant complications.

In the 1990s, in sports medicine, the role of correction of varus malalignment in the treatment of ligamentous injuries and imbalance of the knee led to a reappraisal of osteotomy.² Furthermore, new knowledge led to renewed interest in the influence of malalignment on the development and symptoms of osteoarthritis.³⁻⁵

Recently, better guidelines have been formulated for the selection of candidates for osteotomy by The International Society of Arthroscopy, Knee Surgery and Orthopaedic Sports Medicine (ISAKOS).⁶ New techniques for medial-opening-wedge osteotomy⁷ and specially designed fixation plates based on the locking-compression-plate (LCP) concept, providing superior initial stability, are now available.⁸⁻¹²

These factors have led to a trend back towards osteotomy around the knee. This paper discusses the current views on high tibial osteotomy (HTO).

Indication, patient selection and prognosis

The main indication for HTO is the correction of varus malalignment in medial unicompartamental osteoarthritis of the knee. The aim is to unload the medial compartment by slightly

overcorrecting into valgus, in order to reduce pain, slow the degenerative process and delay joint replacement.^{1,13-20} A second indication is the correction of load imbalance in ligamentous instability in patients with a varus thrust in order to change the axial alignment, thereby reducing the varus thrust and unloading any ligament reconstruction. A possible secondary goal in these patients is to change the tibial slope in order to reduce translational forces and improve the anteroposterior stability of the knee.

In the initial assessment weight-bearing anteroposterior (AP) and lateral radiographs and axial views of the patellofemoral joint are taken as well as whole-leg standing radiographs in order to assess alignment. Abnormal ligamentous laxity is noted on clinical examination and on optional stress radiographs. The presence of a constitutional varus morphotype and previous meniscal procedures is documented. The tibial bone varus angle (TBVA) (Fig. 1) and the patellar height should be measured. In 2004 the place of osteotomies and UKR in the management of osteoarthritis of the knee was formulated by ISAKOS. For each treatment option ideal patients, possible patients and patients not suited for surgery were defined (Table I). In addition to these guidelines, we believe that patients younger than 40 years of age can benefit from realignment alone, or combined with a secondary cartilage procedure such as microfracture for osteochondritis or early osteoarthritis. Ligamentous reconstruction can be combined with osteotomy to modify frontal and sagittal planes.^{2,21} Corrections of > 15° can be performed with current techniques of fixation of the osteotomy.

■ J.-M. Brinkman, MD,
Orthopaedic Resident
■ A. B. Wymenga, MD, PhD,
Orthopaedic Surgeon
■ R. J. van Heerwaarden, MD,
PhD, Orthopaedic Surgeon
Department of Orthopaedics
Limb Deformity Reconstruction
Unit, Sint Maartenskliniek,
Hengstdal 3, 6522 JV,
Nijmegen, The Netherlands.

■ P. Lobenhoffer, MD, PhD,
Professor
■ J. D. Agneskirchner, MD,
PhD, Orthopaedic Surgeon
Klinik für Unfall- und
Wiederherstellungschirurgie,
Henriettenstiftung Hannover,
Marienstrasse 72-90, 30171
Hannover, Germany.

■ A. E. Staubli, MD,
Orthopaedic Surgeon
Klinik für Orthopädie, Luzern
Kantonsspital 6000, Luzern 61,
Switzerland.

Correspondence should be sent
to Dr R. J. van Heerwaarden;
e-mail: r.vanheerwaarden@
maartenskliniek.nl

©2008 British Editorial Society
of Bone and Joint Surgery
doi:10.1302/0301-620X.90B12.
21198 \$2.00

J Bone Joint Surg [Br]
2008;90-B:1548-57.

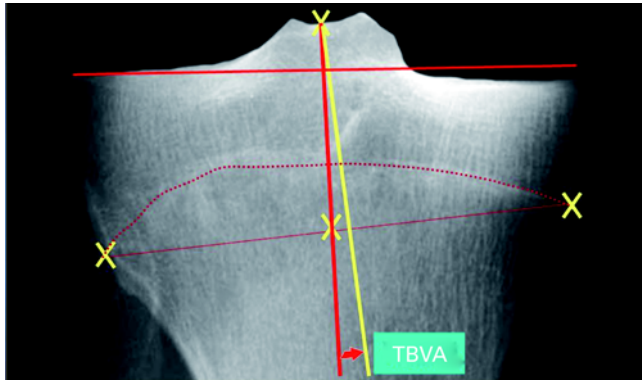


Fig. 1

Radiograph showing the tibial bone varus angle (TBVA) (arrow), which is the angle between the mechanical axis of the tibia (red line) and the epiphyseal axis of the proximal tibia (yellow line).²²

For UKR, ISAKOS defined the ideal patient as aged ≥ 65 yrs, with a sedentary lifestyle, an osseous deformity (TBVA) $< 5^\circ$ and a leg deformity correctable by physical examination and assessed on stress radiographs. Ligamentous stability, a full range of movement and absence of tibiofemoral subluxation were defined as prerequisites. In terms of prognosis, Bonnin and Chambat²² looked at tibial deformities and measured the TBVA, concluding that it was an important prognostic factor. High tibial osteotomy was more or less curative in patients with an abnormal TBVA ($> 5^\circ$). The osteotomy corrected the congenital deformity in these patients and normalised the obliquity of the joint line while it was palliative in patients with a normal TBVA

($< 5^\circ$). If patients are selected for osteotomy based on the TBVA, a successful result is obtained in $> 90\%$ at ten years' follow-up.²² Jenny et al²³ identified similar results.

Babis et al²⁴ also looked at obliquity of the joint line as a prognostic factor. In a series of patients with large varus deformities and osteoarthritis of the medial compartment, they demonstrated in a computer model that, with a double osteotomy combining a distal femoral with a proximal tibial osteotomy, normal obliquity of the joint line was preserved. The tension of stabilising ligaments also remained normal by correcting a varus alignment into slight valgus. Their 29 simulated double osteotomies were performed in 24 patients and resulted in a 96% survival rate at a mean follow-up of 82.7 months. They concluded that preservation of obliquity of the joint line within narrow boundaries of 0° (SD 4) was the key to success. This has been confirmed in a more recent short-term follow-up study by Hofmann and van Heerwaarden.²⁵

However, few studies that have documented the survival of HTO use survival curves calculated by the Kaplan-Meier method. The endpoint is usually insertion of a TKR; prognostic factors for survival are rarely used. Coventry, Ilstrup and Wallrichs²⁶ recorded a survival rate of 87% at five years and 66% at ten years. They found a lower survival rate in patients who were obese (51% vs 91%) and a higher survival in patients who had a valgus alignment $\geq 8^\circ$ five weeks' post-operatively, compared to those who had a valgus alignment $\leq 5^\circ$ (94% vs 63%). Similarly, Naudie et al²⁷ observed that obesity and failure to achieve adequate correction were negative prognostic factors. Holden et al²⁸ and Odenbring et al²⁹ noted an age of < 50 years to be a positive prognostic factor.

Table I. Ideal and possible patients for high tibial osteotomy and patients not suited for the procedure according to the International Society of Arthroscopy, Knee Surgery and Orthopaedic Sports Medicine⁶

Ideal [†]	Possible [†]	Not suited
Isolated medial joint line pain	Flexion contracture $< 15^\circ$	Bi-compartmental (medial and lateral) OA [‡]
Age (yrs) 40 to 60	Previous infection	Fixed flexion contracture $> 25^\circ$
BMI < 30	Age 60 to 70 or < 40	Obese patients
High-demand activity but no running or jumping	ACL, PCL or PLC insufficiency	Meniscectomy in the compartment to be loaded by the osteotomy
Malalignment $< 15^\circ$	Moderate patellofemoral arthritis	
Metaphyseal varus, i.e. TBVA $> 5^\circ$	Wish to continue all sports	
Full range of movement		
Normal lateral and patellofemoral components		
IKDC (A) B, C, D/Ahlback I to IV ⁸⁰		
No cupula		
Normal ligament balance		
Non-smoker		
Some level of pain tolerance		

* BMI, body mass index; TBVA, tibial bone varus angle; IKDC, International Knee Documentation Committee osteoarthritis classification

† ACL, anterior cruciate ligament; PCL, posterior cruciate ligament; PLC, posterolateral corner

‡ OA, osteoarthritis

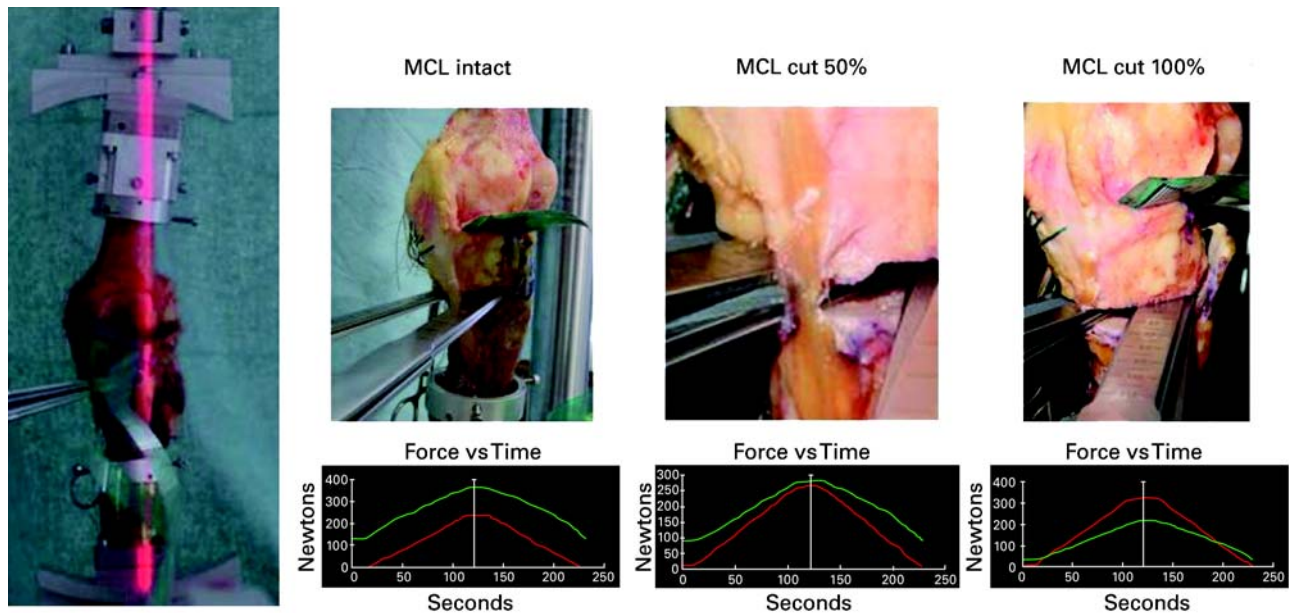


Fig. 2

Photographs showing cartilage pressure distribution in high tibial osteotomy (HTO). Biomechanical test set-up for pressure-film measurements in the medial and lateral compartments of the knee while simulating an opening-wedge HTO. A vertically projected laser beam shows that the loading axis passes the knee joint at the Fujisawa point.¹⁷ Graphs showing pressure distribution in the medial (green line) and lateral (red line) compartments after a valgus opening-wedge osteotomy with an intact medial collateral ligament (MCL), and after dividing the MCL by 50% and 100%. Only a full release of the MCL distal to the opening-wedge HTO will cause a cartilage pressure redistribution to the lateral compartment.⁴⁷

Correction of the deformity

Classically, the correction is usually performed in the tibia. This is contraindicated in knee joints that have an oblique joint line, as the subsequent tibial osteotomy causes an increase in obliquity. This is also true in patients where a distal femoral deformity causes a varus malalignment of the axis.³⁰ Generally, the principles of the correction of deformity as formulated by Paley³¹ should be respected.

A lateral closing-wedge, a medial opening-wedge or a dome-type tibial osteotomy may be used.^{15,32} Many studies have shown good short- and mid-term follow-up results for the various techniques of osteotomy.^{19,26,33-37} The outcome, however, strongly depends on an optimal and exact amount of correction.³⁸ Too little correction leads to poor results and a recurrence of the varus malalignment; too much leads to a valgus overload and osteoarthritis of the lateral compartment.¹⁸⁻²⁰

For a valgus HTO, post-operative corrections from 8° to 10° valgus relative to the anatomical axis, and 3° to 5° valgus relative to the mechanical axis, have been proposed^{18,19,39-43} More recent authors have used the position of the mechanical leg axis relative to the width of the tibial plateau, pre- and post-operatively, as a guideline for the amount of correction needed.⁴⁴ Their recommendations are based on the work of Fujisawa et al,¹⁷ who concluded that, for optimal results, the corrected axis should run through the lateral 30% to 40% of the tibial plateau. Based on this clinical work, it is recommended by many that the post-operative mechanical axis

should run laterally through the tibial plateau, at 62% of its entire width, measured from the medial side.⁴⁵⁻⁴⁷

Some experimental data⁴⁸ on the effect of different axes of loading after osteotomy on the pressure distribution across the surface of the knee joint, measured using pressure-sensitive films, is available. In the only study performed under reproducible dynamic loading conditions, Agneskirchner et al⁴⁷ measured the pressure distribution across the joint, before and after an opening-wedge HTO, with the corrected axis running through the 'Fujisawa point',¹⁷ with an intact medial collateral ligament (MCL), and after stepwise cutting of the MCL (Fig. 2). In varus alignment, most pressure was medial (65%), in neutral alignment it was also medial (60%), and in valgus alignment it was lateral (65%). After an opening-wedge osteotomy with an intact MCL, the pressure increased medially (71%). Only after complete transection of the MCL did the pressure change to 64% laterally. They concluded that decompression of the medial compartment in an opening-wedge osteotomy is possible and effective by using a slight valgus overcorrection, i.e. through the Fujisawa point, but not without a release of the MCL.

With respect to correction of the slope, joint pressure and translational forces in the sagittal plane can be strongly influenced by changing the tibial slope. Neyret, Zuppi and Selmi⁴⁹ found a strong relationship between increased tibial slope and increased anterior tibial translation, with a normal slope being 10° (SD 3). Generally, reducing the slope will correct for the increased anterior tibial translation in

Table II. Comparison of fixation methods

Method	Advantages	Disadvantages
Cylinder cast only	Simple Cheap Exposure only required for saw cuts	Delayed bone healing ⁸¹ Loss of correction ⁸² Immobilisation and its complications*
External fixation	Gradual correction of large deformities possible Angle of correction can be changed ^{32,83}	Bulky device Inconvenient for patients Pin-track-related complications ⁸⁴
Lateral osteotomy with staple fixation	Simpler and quicker than plate fixation Larger contact area after osteotomy closure	Requires casting Poor holding power of staples ³² Loss of correction ⁸⁵ Complications of lateral approach [†] Large offset created in lateral proximal tibia ^{86,87}
Lateral osteotomy with fixation plate	More stable than staples ⁸⁵ No casting required Immediate knee movement allowed Large contact area after osteotomy closure	Complication of lateral approach [†] Large offset created in lateral proximal tibia
Medial osteotomy with fixation plate	No lateral approach Simpler medial approach Only one saw cut needed Transverse/sagittal plane corrections possible No offset created	High initial demand on implant No large contact area Small lateral hinge ⁸⁸ No compression of osteotomy possible Fixation failure ^{74,89}
Angle stable implants; applied either lateral or medial	Less damage to periosteum and soft tissues ⁵⁶ No rigid compression needed Higher initial stability ^{58,59}	Relatively bulky implants Expensive

* arthrofibrosis, increased risk of venous thrombosis, stiffness, muscle atrophy

† muscle detachment, peroneal nerve dissection, fibular osteotomy required, leg shortening

anterior cruciate ligament (ACL)-deficient knees and will reduce stresses on the ACL reconstruction improving anteroposterior stability. However, increasing the slope will reduce translation in posterior cruciate ligament (PCL)-deficient knees. Agneskirchner et al⁵⁰ found that changes in tibial slope have a strong effect on the kinematics of the knee. They measured contact pressure after tibial flexion osteotomies which increased the tibial slope, and found a reduction of pressure in the posterior part of the tibial plateau. With this technique secondary cartilage damage in ACL-deficient knees, which is usually located in the posterior compartment can be unloaded. They concluded that valgus osteotomies can be combined with a flexion component of the proximal tibia, addressing complex knee pathologies which might possibly comprise damage to the posteromedial cartilage and anteroposterior and posterolateral instability, in one procedure. There is further recent evidence that the slope increases after open-wedge osteotomy and decreases after closed-wedge osteotomy.⁵¹

Techniques of osteotomy and methods of fixation

Most techniques of HTO are lateral-based closing-wedge procedures.¹⁵ All require either a fibular osteotomy or a release of the proximal tibiofibular joint, require osteosynthesis on the

lateral side of the tibia and cause shortening. Large corrections may cause marked shortening of the leg and a large offset of the proximal tibia, which may compromise later placement of the tibial component of a TKR. Two saw cuts are needed, and only malalignment in the frontal plane can be corrected. The exposure required on the lateral side includes release of the extensor musculature and risks damage to the common peroneal nerve. This is said to occur in between 3.3% and 11.9% of patients, and indeed electromyography shows damage in up to 27% of patients.^{52,53}

Medial opening-wedge techniques of HTO, avoid muscle detachment, dissection of the peroneal nerve, shortening of the leg and fibular osteotomy. Only one saw cut is required, and corrections in the frontal plane can be combined with adjustments in the sagittal plane. However, these procedures have been less popular, mainly because implants for internal fixation have, until recently, been unable to withstand the axial and torsion forces in the proximal tibia. Several implant-related complications have been reported (Table II). Another cause of failure is that if the osteotomy cut is made above the tibial tuberosity, little room is left for proximal fixation. A modification of the opening-wedge technique has been proposed in the form of a biplanar osteotomy in which a transverse cut is combined with a




Fig. 3a

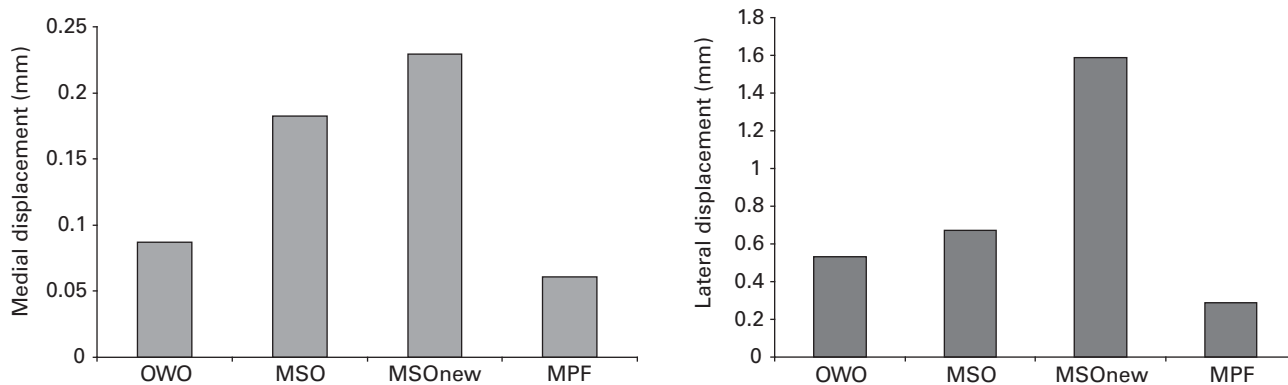


Fig. 3b

Photograph showing a) biomechanical test set-up for the measurement of displacement at the medial (left frame) and lateral (right frame) sides of a medial opening-wedge HTO during axial loading of third-generation composite tibiae and the different plates used and graphs showing b) medial and lateral linear displacement transducer measurements of the four tested implants: conventional spacer plate without locking bolts (OWO), short spacer plate with multidirectionally-insertable locking bolts (MSO), long spacer plate with multidirectionally insertable locking bolts (MSOnew), and medial tibial plate fixator (MPF). The MPF shows significantly less displacement during axial loading than the other implants.⁵⁸

second ascending cut behind the tuberosity.⁷ With this technique more room is left for proximal fixation and a buttress is created which provides stability in the sagittal and transverse planes.

Various methods of fixation have been used and these are summarised in Table II. Based on the principle that bone healing is induced by the micromovement which occurs across a splinted zone, a variety of plates have been developed over the last 20 years, including locking compression plates (LCP), the point contact fixation system (PC-fix) and the less invasive stabilisation system (LISS).^{10,11,54-56} they all consist of an angle-stable plate-screw interface of locking bolts, which increase the stiffness of the construct and

obviate the need for rigid compression of the plate against bone. With the LCP a combination screw hole was introduced which can be used both for conventional fixation with rigid compression, and for splinting. Good clinical results using these plates have been reported in treating fractures.^{9,57}

These principles have been applied to the fixation of osteotomies. Plate fixators have been developed based on the LCP concept for opening- and closing-wedge osteotomies. For an opening-wedge osteotomy a long, T-shaped fixator plate is available (Tomofix; Synthes GmbH; Solothurn, Switzerland).⁸ The initial stability provided by this implant has been investigated in a biomechanical study by Agneskirchner et al⁵⁸ using third generation composite tibiae as a model,

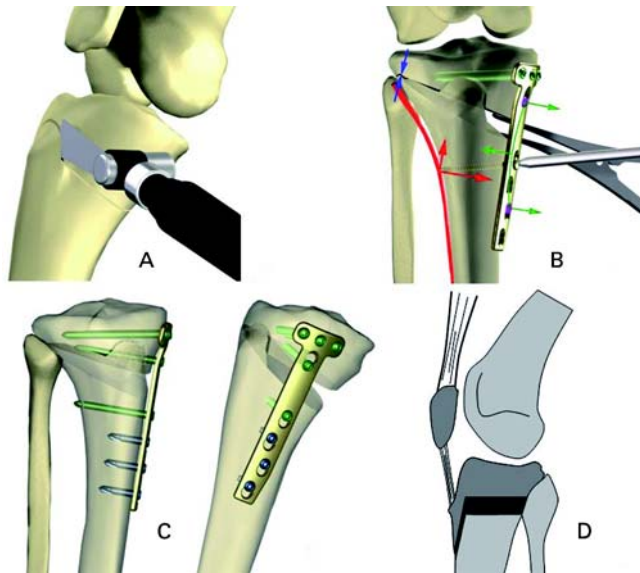


Fig. 4

Diagrams showing surgical technique for a biplane opening-wedge HTO with fixation by an internal fixator plate. The ascending cut of the biplane osteotomy is performed behind the tibial tuberosity (A). A lag-screw is (green arrow) inserted causing a force vector upwards (red arrows) with lateral hinge-point compression (blue arrows) (B). Configuration of the final fixation configuration in frontal and sagittal views (C). Modification of surgical technique: distal tuberosity cut to prevent patella infera in large opening-wedge corrections (D).⁶³

four different plates were tested: three types of spacer plate of different lengths, two with locking bolts, and the Tomofix plate fixator (Fig. 3). The authors applied axial compression on the tibiae using a materials testing machine under standardised alignment of the loading axis. Single load-to-failure tests and load-controlled cyclical tests to failure were performed. Failure occurred at the bone bridge of the lateral cortex in all tested implants. In the single load-to-failure tests the Tomofix plate resisted the most force. In the cyclical load-to-failure tests it resisted more than twice the amount of loading cycles than did the short spacer plates. The movement at the osteotomy gap was smallest in the Tomofix, with a reduction in displacement of between 65% and 88% compared to the various spacer plates. The highest residual stability after failure of the lateral cortex was also observed with the Tomofix plate. These results suggest that the design of the implant strongly influences the primary stability of a medial opening-wedge tibial osteotomy. Agneskirchner et al⁵⁸ concluded that a rigid long-plate fixator with locking bolts yielded the best results.

The clinical results seem to correlate with these biomechanical observations. Lobenhoffer and Agneskirchner⁷ reported a 6% rate of failure of the implant with loss of correction in a series of 101 HTOs using a spacer plate. Spahn⁵⁹ compared spacer plates with an angle-stable implant and found that 11.7% of patients treated with a spacer plate needed additional lateral osteosynthesis. Loss of correction related to the implant was seen only in patients treated with

a spacer plate. Staubli et al⁸ investigated 92 HTOs treated with a Tomofix plate and observed 2% loss of correction and 2% delayed union. Lobenhoffer, Agneskirchner and Zoch⁶⁰ described 262 consecutive HTOs using a Tomofix plate with no loss of correction, although two patients developed a pseudarthrosis, both successfully treated with cancellous bone graft.

Operative technique

When the authors carry out a valgus HTO biplanar medially-based opening-wedge osteotomy, fixation is with the Tomofix plate (Fig. 4).⁶¹

Arthroscopy may be performed routinely before HTO in order to debride the degenerate compartment and to check the integrity of the other side. In some cases the arthroscopic assessment will lead to a change in surgical intervention, and therefore, arthroscopy is regarded by some as indispensable before HTO.⁶² The starting position of the procedure is with the knee flexed to 90°. A fluoroscope is mandatory, with visualisation possible in two directions. The medial side of the tibia is exposed through either a transverse or a longitudinal incision. The superficial fibres of the medial collateral ligament are mobilised and a distal release is performed. The upper border of the pes anserinus marks the starting point of the osteotomy. Two Kirschner wires are placed under fluoroscopic control to mark the saw cut. The lateral aiming point is the upper third of the proximal tibiofibular joint, 10 mm medial to the lateral cortex. This is the hinge point of the osteotomy. Only the posterior two-thirds of the tibia are cut. The separate ascending cut of the biplanar osteotomy is performed 1.5 cm to 2 cm behind the tibial tuberosity in the frontal plane, parallel to the anterior tibial margin (Fig. 4).

The osteotomy is opened gradually using chisels and a specially-calibrated spreading device. The gap is then measured and compared with the planned length of the base of the wedge. If the desired correction is achieved, and checked further with a rigid bar projected over the centres of the hip and ankle, a laminar bone spreader is inserted. It is essential to obtain full extension during these measurements which sometimes means that the lateral hinge may be fractured and later compressed during fixation. The plate fixator is introduced into the wound and then pushed distally into a subcutaneous tunnel until its long arm is aligned with the tibial shaft. Eight locked bolts are used in the Tomofix device, four proximal and four distal, of which three are unicortical. An additional lag screw is applied through the first distal hole below the osteotomy after proximal fixation, inducing compression on the lateral hinge point of the osteotomy and eliminating any potential distraction or instability in this area (Fig. 4).

A modification of the biplanar osteotomy can be used, especially in large opening-wedge corrections, or in cases of pre-operative patella infera. Instead of making the second osteotomy cut proximally, the tibial tuberosity is cut distally (Fig. 4).⁶³

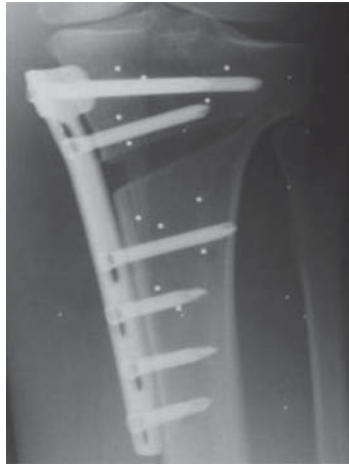


Fig. 5a

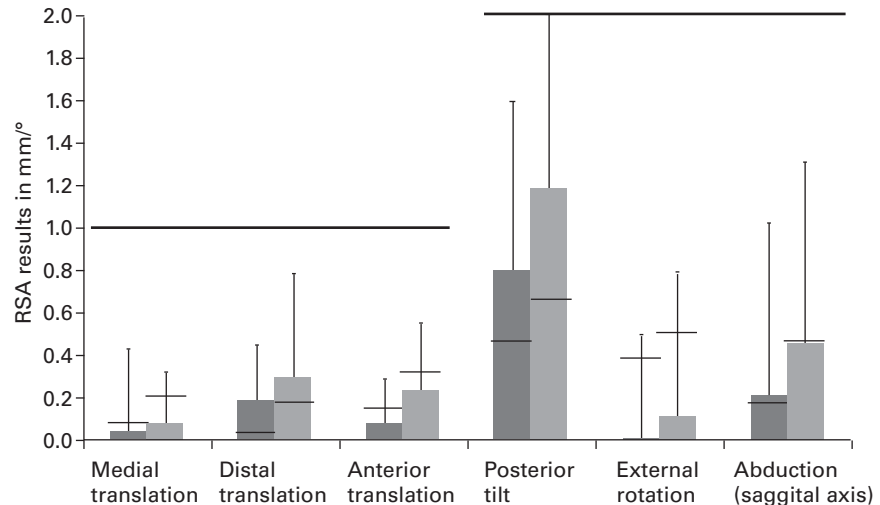


Fig. 5b

Roentgen stereophotogrammetric analysis (RSA) measurements of fixation stability in post-operative rehabilitation. a) Radiograph showing RSA bone markers inserted proximal and distal of an opening wedge HTO and b) bar chart showing the mean displacements of RSA markers inserted proximal and distal to an opening-wedge HTO during the first 12 months after surgery. Rehabilitation, with early post-operative full weight-bearing (dark grey bars) compared to full weight-bearing after six weeks (light grey bars).^{69,70}

The supposed effects of alterations in patellar height in HTO⁶⁴⁻⁶⁶ have been studied by Gaasbeek et al.⁶³ They compared the effects on patellar height, calculated using the Caton Index,⁶⁷ in patients who had undergone a standard proximal-tuberosity osteotomy (PTO) and a modified distal-tuberosity osteotomy (DTO). They found that patellar height does not change with the latter, but in PTO it decreased significantly. In the latter group, patellar height and the angle of correction were related: the larger the correction angle, the lower the post-operative patellar height. Based on these results, they concluded that a DTO can prevent changes in patellar height, and recommended that it should be performed in patients who require a large correction. In a recent study by Stoffel et al⁶⁸ both techniques were compared by measuring patellofemoral contact stress. A DTO produced significantly less contact stress than did the PTO technique. We use a DTO in those patients with a pre-existing low patella, and consider it in opening-wedge corrections > 8° to 10°.

Post-operative care and weight-bearing protocol

Post-operative cryotherapy and intermittent venous compression are recommended to reduce swelling. Starting on the first post-operative day, partial weight-bearing (15 kg to 20 kg) is allowed. From four to six weeks the amount of weight-bearing allowed is based on the amount of pain, although after six weeks full weight-bearing is permitted. A full range of active and passive movement is encouraged, and started with the help of a physiotherapist.

Two studies have been performed to investigate the weight-bearing protocol and the stability of fixation. Luites et al⁶⁹ in a randomised prospective clinical trial, compared

stability between opening-wedge and closing-wedge HTO with the Tomofix plate fixator in 42 patients, using Roentgen stereophotogrammetric analysis (RSA) (Fig. 5). All patients were allowed immediate partial weight-bearing for a period of six weeks and full weight-bearing thereafter. Roentgen stereophotogrammetric analysis measurements made immediately after surgery and at six weeks, three, six and 12 months post-operatively were compared to measured micromovements at the osteotomy. They found no difference between the two techniques and no significant displacement compared to measurements made immediately after surgery. In a second study, Brinkman et al⁷⁰ measured the stability of fixation using the same RSA technique in 14 opening-wedge osteotomies with full weight-bearing starting two weeks after surgery. Again, no significant movement at the osteotomy was recorded (Fig. 5). The authors concluded that fixation was stable without loss of correction with early weight-bearing.

Early weight-bearing can be started depending on pain and wound healing. Most patients are fully weight-bearing after two to three weeks.

Bone healing in HTO

The general principles of bone healing apply to closing-wedge osteotomies, which can be considered as optimally controlled fractures treated according to the standard protocol of fracture treatment. With radiographs taken at distinct intervals, e.g. at six weeks, three, six and 12 months, progression of bone healing can be monitored.

Bone healing in opening-wedge osteotomies differs, however, because of the distraction and the gap which is created. Staubli⁷¹ extensively studied bone healing in HTO

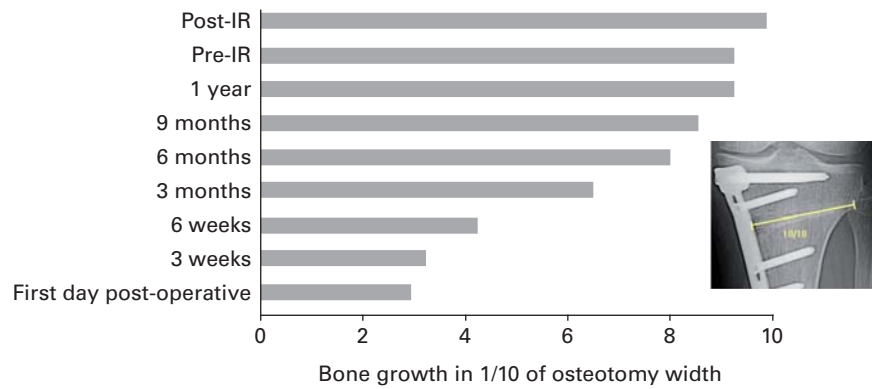


Fig. 6a

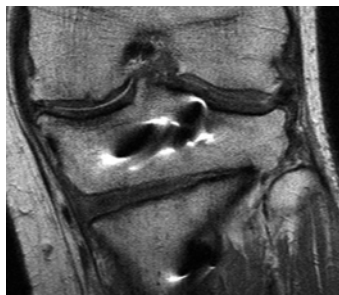


Fig. 6b

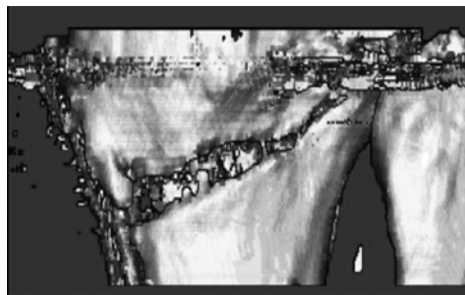
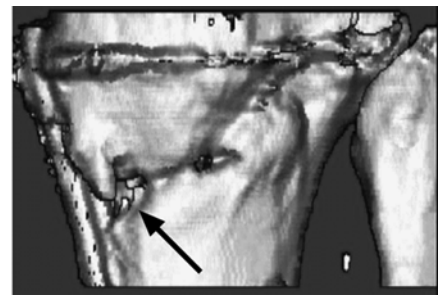


Fig. 6c



Bone healing in an open wedge HTO. Bar chart showing a) progression of bone growth in an osteotomy gap related to the width of the osteotomy starting at the laterally based hinge point.⁷¹ IR, implant removal, MR (T1) image showing b) callus formation and ossification three months after HTO and c) three-dimensional CT images six weeks (left) and six months (right) after an opening-wedge HTO (posterolateral view) showing progression in bone mineralisation but no full consolidation at six months post-operatively (arrow).

performed without filling the gap and found that on plain radiographs healing occurs from lateral to medial, starting at the laterally-based hinge point (Fig. 6).

On MR scans, at six weeks the haematoma in the gap is replaced by connective tissue, which provides a scaffold for further callus formation and ossification, visible by three months post-operatively (Fig. 6). Based on the assessment of standard radiographs, approximately 75% of the gap has filled with new bone by six months. CT scans at this point show progression in bone mineralisation but no signs of full consolidation, indicating that bone healing is over-estimated at six months on standard radiographs, with the CT scans showing progression at a slower pace (Fig. 6).

One year after operation full consolidation can be found in approximately 90% of patients on radiographs, MRI and CT scans. We do not advise removal of the plate before 1.5 years after osteotomy.

Many surgeons, however, prefer to fill the gap with bone graft. This view is based on various arguments, such as a reduction in local blood loss, an increase in mechanical stability and an increase in bone healing.⁷²⁻⁷⁷

In one of our centres (Sint Maartenskliniek, Nijmegen, The Netherlands) opening-wedge HTO has been performed using Tomofix plates and porous tri-calcium phosphate (TCP) as a

filling material. Resorption of TCP, bone ingrowth and bone remodelling were studied on plain radiographs⁷⁸ and on bone biopsies from the areas of the opening-wedge at the time of removal of the plate.⁷⁹ It was found that the TCP was resorbed, with complete incorporation and remodelling into new bone.⁷⁹ Based on this, our view is that when using a stable implant in biplanar opening-wedge HTO, only gaps > 20 mm should be filled. We advise that autologous grafts be used. If filling material is preferred, porous TCP is a safe option that will not interfere with normal bone healing. However, no prospective randomised trials have yet been published that compare the various filling materials with no filling at all.

High tibial osteotomy is a viable treatment option for a well-defined patient group suffering from osteoarthritis of the medial compartment and ligamentous imbalance of the knee. Based on new data obtained by biomechanical testing and clinical research, the biplanar osteotomy fixed with an internal plate fixator is very stable. Although bone healing in opening-wedge osteotomies may take from as little as three up to 12 months, early full weight-bearing is possible with these stable plates and good bone healing is achieved without loss of correction.

No benefits in any form have been received or will be received from a commercial party related directly or indirectly to the subject of this article.

References

1. Coventry MB. Osteotomy of the upper portion of the tibia for degenerative arthritis of the knee: a preliminary report. *J Bone Joint Surg [Am]* 1965;47-A:984-90.
2. Noyes FR, Barber SD, Simon R. High tibial osteotomy and ligament reconstruction in varus angulated, anterior cruciate ligament-deficient knees: a two-to seven-year follow-up study. *Am J Sports Med* 1993;21:2-12.
3. Cicuttini F, Wluka A, Hankin J, Wang Y. Longitudinal study of the relationship between knee angle and tibiofemoral cartilage volume in subjects with knee osteoarthritis. *Rheumatology (Oxford)* 2004;43:321-4.
4. Cerejo R, Dunlop DD, Cahue S, et al. The influence of alignment on risk of knee osteoarthritis progression according to baseline stage of disease. *Arthritis Rheum* 2002;46:2632-6.
5. Schmitt E, Heisel J, Jani L, Schumacher G. Kniegelenknahe Beinachsenfehlstellung. Deutsch Gesellschaft für Orthopädie und Orthopädische Chirurgie. Leitlinien der Orthopädie. 2002. Köln, Deutscher Ärzte-Verlag. <http://www.uni-duesseldorf.de/awmf/11/038-005.htm> (date last accessed 8 July 2008).
6. Rand JA, Neyret P. ISAKOS meeting on the management of osteoarthritis of the knee prior to total knee arthroplasty. *ISAKOS Congress*, 2005.
7. Lobenhoffer P, Agneskirchner JD. Improvements in surgical technique of valgus high tibial osteotomy. *Knee Surg Sports Traumatol Arthrosc* 2003;11:132-8.
8. Staubli AE, De Simon C, Babst R, Lobenhoffer P. TomoFix: a new LCP-concept for open wedge osteotomy of the medial proximal tibia: early results in 92 cases. *Injury* 2003;34(Suppl 2):55-62.
9. Sommer C, Gautier E, Muller M, Helfet DL, Wagner M. First clinical results of the Locking Compression Plate (LCP). *Injury* 2003;34(Suppl 2):43-54.
10. Wagner M, Frenk A, Frigg R. New concepts for bone fracture treatment and the Locking Compression Plate. *Surg Technol Int* 2004;12:271-7.
11. Wagner M. General principles for the clinical use of the LCP. *Injury* 2003;34(Suppl 2):31-42.
12. Stoffel K, Dieter U, Stachowiak G, Gächter A, Kuster MS. Biomechanical testing of the LCP: how can stability in locked internal fixators be controlled? *Injury* 2000;34(Suppl 2):11-19.
13. Maquet P. The treatment of choice in osteoarthritis of the knee. *Clin Orthop* 1985;192:108-12.
14. Maquet P. Valgus osteotomy for osteoarthritis of the knee. *Clin Orthop* 1976;120:143-8.
15. Lobenhoffer P, De Simon C, Staubli AE. Open-wedge high-tibial osteotomy with rigid plate fixation. *Techniques in Knee Surgery* 2002;1:93-105.
16. Outerbridge RE. The etiology of chondromalacia patellae. *J Bone Joint Surg [Br]* 1961;43-B:752-7.
17. Fujisawa Y, Masuhara K, Shiomi S. The effect of high tibial osteotomy on osteoarthritis of the knee: an arthroscopic study of 54 knee joints. *Orthop Clin North Am* 1979;10:585-608.
18. Hernigou P, Medevielle D, Debeyre J, Goutallier D. Proximal tibial osteotomy for osteoarthritis with varus deformity: a ten to thirteen-year follow-up study. *J Bone Joint Surg [Am]* 1987;69-A:332-54.
19. Ivarsson I, Myrnerets R, Gillquist J. High tibial osteotomy for medial osteoarthritis of the knee: a 5 to 7 and 11 year follow-up. *J Bone Joint Surg [Br]* 1990;72-B:238-44.
20. Tjornstrand B, Egund N, Hagstedt B, Lindstrand A. Tibial osteotomy in medial gonarthrosis: the importance of over-correction of varus deformity. *Arch Orthop Trauma Surg* 1981;99:83-9.
21. Imhoff AB, Linke RD, Agneskirchner J. Corrective osteotomy in primary varus, double varus and triple varus knee instability with cruciate ligament replacement. *Orthopade* 2004;33:201-7 (in German).
22. Bonnin M, Chambat P. Current status of valgus angle, tibial head closing wedge osteotomy in medial gonarthrosis. *Orthopade* 2004;33:135-42 (in German).
23. Jenny JY, Tavan A, Jenny G, Kehr P. Long-term survival rate of tibial osteotomies for valgus gonarthrosis. *Rev Chir Orthop Reparatrice Appar Mot* 1998;84:350-7 (in French).
24. Babis GC, An KN, Chao EY, Rand JA, Sim FH. Double level osteotomy of the knee: a method to retain joint-line obliquity. *J Bone Joint Surg [Am]* 2002;84-A:1380-8.
25. Hofmann S, van Heerwaarden RJ. Allgemeine Patientenauswahl und Indikationen zu Doppelosteotomien. *Orthopädische Praxis* 2007;43:142-6 (in German).
26. Coventry MB, Ilstrup DM, Wallrichs SL. Proximal tibial osteotomy: a critical long-term study of eighty-seven cases. *J Bone Joint Surg [Am]* 1993;75-A:196-201.
27. Naudie D, Bourne RB, Rorabeck CH, Bourne TJ. Survivorship of the high tibial valgus osteotomy: a 10- to 22-year followup study. *Clin Orthop* 1999;327:18-27.
28. Holden DL, James SL, Larson RL, Sloucom DB. Proximal tibial osteotomy in patients who are fifty years old or less: a long-term follow-up study. *J Bone Joint Surg [Am]* 1988;70-A:977-82.
29. Odenbring S, Tjornstrand B, Egund N, et al. Function after tibial osteotomy for medial gonarthrosis below aged 50 years. *Acta Orthop Scand* 1989;60:527-31.
30. Hofmann S, Pietsch R, van Heerwaarden RJ. Biomechanische Grundlagen und Planung bei Umstellungsosteotomien am Kniegelenk. *Orthopädische Praxis* 2007;43:109-15 (in German).
31. Paley D. *Principles of deformity correction*. New York: Springer-Verlag, 2002.
32. Chandler RW, Seltzer D. Fixation in high tibial osteotomy. In: Fu FH, Harner CD, Vince KG, eds. *Knee surgery*. Baltimore: Williams & Wilkins, 1994:1135-52.
33. Coventry MB. Upper tibial osteotomy for gonarthrosis: the evolution of the operation in the last 18 years and long term results. *Orthop Clin North Am* 1979;10:191-210.
34. Hassenpflug J, von Haugwitz A, Hahne HJ. Long-term results of tibial head osteotomy. *Z Orthop Ihre Grenzgeb* 1998;136:154-61 (in German).
35. Insall JN, Joseph DM, Msika C. High tibial osteotomy for varus gonarthrosis: a long-term follow-up study. *J Bone Joint Surg [Am]* 1984;66-A:1040-8.
36. Odenbring S, Egund N, Knutson K, Lindstrand A, Larsen ST. Revision after osteotomy for gonarthrosis: a 10-19 year follow-up of 314 cases. *Acta Orthop Scand* 1990;61:128-30.
37. Yasuda K, Majima T, Tsuchida T, Kaneda K. A ten- to 15-year follow-up observation of high tibial osteotomy in medial compartment osteoarthritis. *Clin Orthop* 1992;282:186-95.
38. Pape D, Adam F, Rupp S, Seil R, Kohn D. Stability, bone healing and loss of correction after valgus realignment of the tibial head: a roentgen stereometry analysis. *Orthopade* 2004;33:208-17 (in German).
39. Coventry MB. Upper tibial osteotomy for osteoarthritis. *J Bone Joint Surg [Am]* 1985;67-A:1136-40.
40. Engel GM, Lippert FG 3rd. Valgus tibial osteotomy: avoiding the pitfalls. *Clin Orthop* 1981;160:137-43.
41. Kettelkamp DB, Chao EY. A method for quantitative analysis of medial and lateral compression forces at the knee during standing. *Clin Orthop* 1972;83:202-13.
42. Koshino T, Morii T, Wada J, et al. High tibial osteotomy with fixation by a blade plate for medial compartment osteoarthritis of the knee. *Orthop Clin North Am* 1989;20:227-43.
43. Mynerts R. Optimal correction in high tibial osteotomy for varus deformity. *Acta Orthop Scand* 1980;51:689-94.
44. Pape D. Präoperative radiologische Planung von kniegelenknahe Tibiaosteotomien. In: Lobenhoffer P, Agneskirchner JD, Galla M, eds. *Kniegelenknahe osteotomien: indikation, planung, operations technik mit platten fixateuren*. Stuttgart: Georg Thieme Verlag, 2006:29-37.
45. Dugdale TW, Noyes FR, Styer D. Preoperative planning for high tibial osteotomy: the effect of lateral tibiofemoral separation and tibiofemoral length. *Clin Orthop* 1992;274:248-64.
46. Miniaci A, Ballmer FT, Ballmer PM, Jakob RP. Proximal tibial osteotomy: a new fixation device. *Clin Orthop* 1989;246:250-9.
47. Agneskirchner JD, Hurschler C, Wrann CD, Lobenhoffer P. The effects of valgus medial opening wedge high tibial osteotomy on articular cartilage pressure of the knee: a biomechanical study. *Arthroscopy* 2007;23:852-61.
48. Riegger-Krugh C, Gerhart TN, Powers WR, Hayes WC. Tibiofemoral contact pressures in degenerative joint disease. *Clin Orthop* 1998;348:233-45.
49. Neyret P, Zuppi G, Selmi TAS. Tibial deflexion osteotomy. *Operative Techniques in Sports Medicine* 2000;8:61-6.
50. Agneskirchner JD, Hurschler C, Stukenborg-Colsman C, Imhoff AB, Lobenhoffer P. Effect of high tibial flexion osteotomy on cartilage pressure and joint kinematics: a biomechanical study in human cadaveric knees. *Arch Orthop Trauma Surg* 2004;124:575-84.
51. El-Azab H, Halawa A, Anetzberger H, Imhoff AB, Hinteruimmer S. The effect of closed- and open-wedge high tibial osteotomy on tibial slope: a retrospective radiological review of 120 cases. *J Bone Joint Surg [Br]* 2008;90-B:1193-7.
52. Aydogdu S, Cullu E, Arac N, Varolgunes N, Sur H. Prolonged peroneal nerve dysfunction after high tibial osteotomy: pre- and postoperative electrophysiological study. *Knee Surg Sports Traumatol Arthrosc* 2000;8:305-8.
53. Aydogdu S, Yercan H, Saylam C, Sur H. Peroneal nerve dysfunction after high tibial osteotomy: an anatomical cadaver study. *Acta Ortho Belg* 1996;62:156-60.
54. Frigg R. Development of the Locking Compression Plate. *Injury* 2003;34(Suppl 2):6-10.
55. Frigg R. Locking Compression Plate (LCP): an osteosynthesis plate based on the Dynamic Compression Plate and the Point Contact Fixator (PC-Fix). *Injury* 2001;32(Suppl 2):63-6.
56. Perren SM. Evolution of the internal fixation of long bone fractures: the scientific basis of biological internal fixation: choosing a new balance between stability and biology. *J Bone Joint Surg [Br]* 2002;84-B:1093-110.
57. Gautier F, Sommer C. Guidelines for the clinical application of the LCP. *Injury* 2003;34(Suppl 2):63-76.
58. Agneskirchner JD, Freiling D, Hurschler C, Lobenhoffer P. Primary stability of four different implants for opening wedge high tibial osteotomy. *Knee Surg Sports Traumatol Arthrosc* 2006;14:291-300.
59. Spahn G. Complications in high tibial (medial opening wedge) osteotomy. *Arch Orthop Trauma Surg* 2004;124:649-53.
60. Lobenhoffer P, Agneskirchner J, Zoch W. Open valgus alignment osteotomy of the proximal tibia with fixation by medial plate fixator. *Orthopade* 2004;33:153-60 (in German).

- 61. Galla M, Lobenhoffer P, Staubli AE.** Die valgusierende öffnende Umstellungsosteotomie der proximalen Tibia mit Plattenfixateur. In: Lobenhoffer P, Agneskirchner JD, Galla M, eds. *Kniegelenknahe Osteotomien: indikation, planung, operations technik mit platten fixateuren*. Stuttgart: Georg Thieme Verlag, 2006:51-64.
- 62. Muller M, Strecker W.** Arthroscopy prior to osteotomy around the knee? *Arch Orthop Trauma Surg* 2007. E pub ahead of print.
- 63. Gaasbeek RD, Sonneveld H, van Heerwaarden RJ, Jacobs WC, Wymenga AB.** Distal tuberosity osteotomy in open wedge high tibial osteotomy can prevent patella infera: a new technique. *Knee* 2004;11:457-61.
- 64. Scuderi GR, Windsor RE, Insall JN.** Observations on patellar height after proximal tibial osteotomy. *J Bone Joint Surg [Am]* 1989;71-A:245-8.
- 65. Wright JM, Heavrin B, Begg M, Sakry G, Sterett W.** Observations on patellar height following opening wedge proximal tibial osteotomy. *Am J Knee Surg* 2001;14:163-73.
- 66. Hernigou P, Ma W.** Open wedge tibial osteotomy with acrylic bone cement as bone substitute. *Knee* 2001;8:103-10.
- 67. Scuderi GR, Windsor RE, Insall JN.** Observations on patellar height after proximal tibial osteotomy. *J Bone Joint Surg [Am]* 1989;71-A:245-8.
- 68. Caton J, Mirronneau A, Walch G, Levigne C, Michel CR.** Ideopathic high patella in adolescents: apropos of 61 surgical cases. *Rev Chir Orthop Reparatrice Appar Mot* 1990;76:253-60 (in French).
- 69. Stoffel K, Willers C, Korshid O, Kuster JM.** Patellofemoral contact pressure following high tibial osteotomy: a cadaveric study. *Knee Surg Sports Traumatol Arthrosc* 2007;15:1094-100.
- 70. Luites JWH, Brinkman JM, van Heerwaarden R, Valstar ER, Wymenga AB.** Stability of open vs closed wedge high tibial osteotomy measured with roentgen stereophotogrammetric analysis in a randomised clinical trial. *ESSKA Congress* 2006.
- 71. Brinkman JM, Luites J, Wymenga AB, van Heerwaarden R.** Early full weight bearing in medial open wedge HTO using an angle stable implant is safe using an RSA analysis of stability. *ESSKA Congress*, 2008.
- 72. Staubli AE.** Radiologische heilungsvorgänge nach öffnender kniegelenknahe Tibiaosteotomie. In: Lobenhoffer P, Agneskirchner JD, Galla M, eds. *Kniegelenknahe Osteotomien: indikation, planung, operations technik mit platten fixateuren*. Stuttgart: Georg Thieme Verlag, 2006:65-78.
- 73. Bonneville P, Abid A, Mansat P, et al.** Tibial valgus osteotomy using a tricalcium phosphate medial wedge: a minimally invasive technique. *Rev Chir Orthop Reparatrice Appar Mot* 2002;88:486-92 (in French).
- 74. Bove JC.** Utilization of a porous alumina ceramic spacer in tibial valgus open-wedge osteotomy: fifty cases at 16 months mean follow-up. *Rev Chir Orthop Reparatrice Appar Mot* 2002;88:480-5 (in French).
- 75. Hernigou P.** A 20-year follow-up study of internal gonarthrosis after tibial valgus osteotomy: single versus repeated osteotomy. *Rev Chir Orthop Reparatrice Appar Mot* 1996;82:241-50 (in French).
- 76. Hernigou P, Ma W.** Open wedge tibial osteotomy with acrylic bone cement as bone substitute. *Knee* 2001;8:103-10.
- 77. Koshino T, Murase T, Saito T.** Medial opening-wedge high tibial osteotomy with use of porous hydroxyapatite to treat medial compartment osteoarthritis of the knee. *J Bone Joint Surg [Am]* 2003;85-A:78-85.
- 78. Seeherman H.** The influence of delivery vehicles and their properties on the repair of segmental defects and fractures with osteogenic factors. *J Bone Joint Surg [Am]* 2001;83-A(Suppl 1):79-81.
- 79. van Hemert WL, Willems K, Anderson PG, van Heerwaarden RJ, Wymenga AB.** Tricalcium phosphate granules or rigid wedge preforms in open wedge high tibial osteotomy: a radiological study with a new evaluation system. *Knee* 2004;1:451-6.
- 80. Gaasbeek RD, Toonen HG, van Heerwaarden RJ, Buma P.** Mechanism of bone incorporation of beta-TCP bone substitute in open wedge tibial osteotomy in patients. *Biomaterials* 2005;26:6713-19.
- 81. Ahlback S.** Osteoarthritis of the knee: a radiographic investigation. *Acta Radiol (Stockh)* 1968;227(Suppl);7-72.
- 82. Jackson JP, Waugh W.** The technique and complications of upper tibial osteotomy: a review of 226 operations. *J Bone Joint Surg [Br]* 1974;56-B:236-45.
- 83. Aglietti P, Rinonapoli E, Stringa G, Taviari A.** Tibial osteotomy for the varus osteoarthritic knee. *Clin Orthop* 1983;176:239-51.
- 84. Zhim F, Laflamme GY, Viens H, Saidana K, Yahia L.** Biomechanical stability of high tibial opening wedge osteotomy: internal fixation versus external fixation. *Clin Biomech (Bristol, Avon)* 2005;20:871-6.
- 85. Hsu RW.** The study of Maquet dome high tibial osteotomy: arthroscopic-assisted analysis. *Clin Orthop* 1989;243:280-5.
- 86. Hartford JM, Hester P, Watt PM, et al.** Biomechanical superiority of plate fixation for proximal tibial osteotomy. *Clin Orthop* 2003;412:125-30.
- 87. Coventry MB.** Stepped staple for upper tibial osteotomy. *J Bone Joint Surg [Am]* 1969;51-A:1011.
- 88. Windsor RE, Insall JN, Vince KG.** Technical considerations of total knee arthroplasty after proximal tibial osteotomy. *J Bone Joint Surg [Am]* 1988;70-A:547-55.
- 89. Miller BS, Dorsey WO, Bryant CR, Austin JC.** The effect of lateral cortex disruption and repair on the stability of the medial opening wedge high tibial osteotomy. *Am J Sports Med* 2005;33:1552-7.
- 90. Goutallier D, Julieron A, Hernigou P.** Cement wedge replacing iliac graft in tibial wedge osteotomy. *Rev Chir Orthop Reparatrice Appar Mot* 1992;78:138-44 (in French).